TUMOUR-LIKE LESIONS IN MULTIPLE SCLEROSIS

Carlos Casimiro[1], Sónia Batista[2], Joana Martins[1], Tiago Parreira[1], Pedro Freitas[1]
[1] Neuroradiology, Hospitais da Universidade de Coimbra, Portugal
[2] Neurology, Hospitais da Universidade de Coimbra, Portugal

Introduction

The presence of tumefactive demyelinating lesions (TDLs) in multiple sclerosis (MS), can cause diagnostic difficulties on MRI, sometimes requiring biopsy, because they can mimic a brain tumour.

Purpose

This study aims to describe TDL MRI appearance and to characterize a series of patients with TDL, identifying the most common clinical presentations, cerebrospinal fluid profile, response to therapy and clinical outcome / prognosis.

Methods

We used a retrospective analysis of clinical files of MS patients with TDL, followed up in Hospitais da Universidade de Coimbra. Inclusion criteria were atypical MRI features of MS, including lesion size >2 cm, mass effect, vasogenic oedema and/or ring enhancement.

Results

- We included 19 patients (median age: 30.8 years).
- 14 females and 5 males were studied.
- Polysymptomatic presentations were found in 78.9% of patients (Table 1).

Symptoms	Freq. (%)
Motor	11 (57.9%)
Cognitive-Behavioral	9 (47.4%)
Sensory	5 (26.3%)
Headache	5 (26.3%)
Brainstem	4 (21.1%)
Cerebellar	3 (15.8%)

Tab. 1.

- Oligoclonal IgG bands (IgG-OCB) in the cerebrospinal fluid (Table 2):

CSF OCB profile	Freq. (%)
Profile 1 (negative)	8 (42.1%)
Profile 2 (positive)	10 (52.6%)
Profile 5 (monoclonal)	1 (5.3%)

Tab. 2.

- Multiple lesions on MRI were found in 79% of patients. The median largest lesion size on T2-WI was 3.6 cm; 31.6% of lesions demonstrated mass effect and 73.7% oedema, with strong association between these three factors.
- After a mean follow-up of 6.3 years, 89.5% converted to clinically definite MS.
- Based on serial MRI studies, stereotactic biopsy and response to treatment, the diagnosis of TDL was confirmed in every case.
- In four patients the diagnosis of MS was carried out by brain or medullar biopsy.

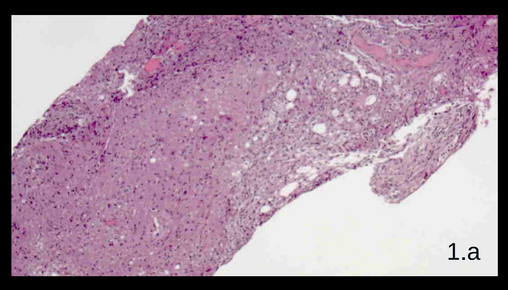

Fig. 1 – Pathology of an active biopsied multiple sclerosis medullar lesion. The features of active inflammatory demyelinating disease consisting of hypercellular lesions with myelin loss. a) and b) Haematoxylin eosin reveals destruction of myelin sheaths and relative axonal preservation. c) Klüver-Barerra. d) Immunohistochemical evaluation of CD68 reveals macrophages.

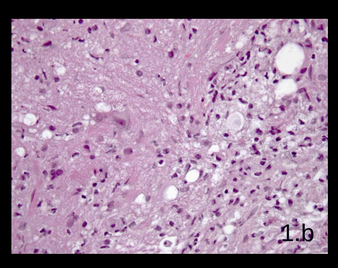

400X

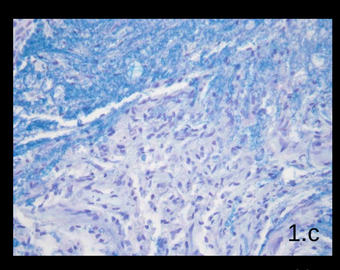

400X

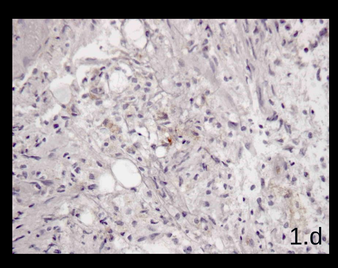

400X

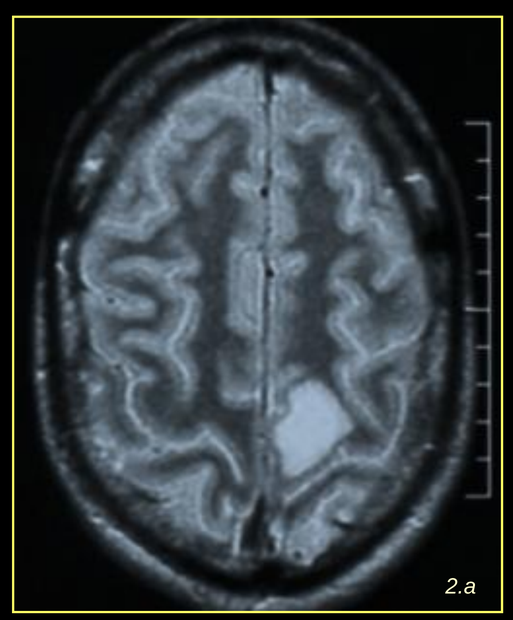

Fig. 2. A 42-year-old male with acute flaccid paralysis of the right leg. The diagnosis of MS was carried out by brain. a) Axial T2-WI. b) Coronal T1-WI.

Fig. 3. A 36-year-old woman with sensory changes. a) and b) Axial FLAIR images. c) Axial post-contrast T1-WI.

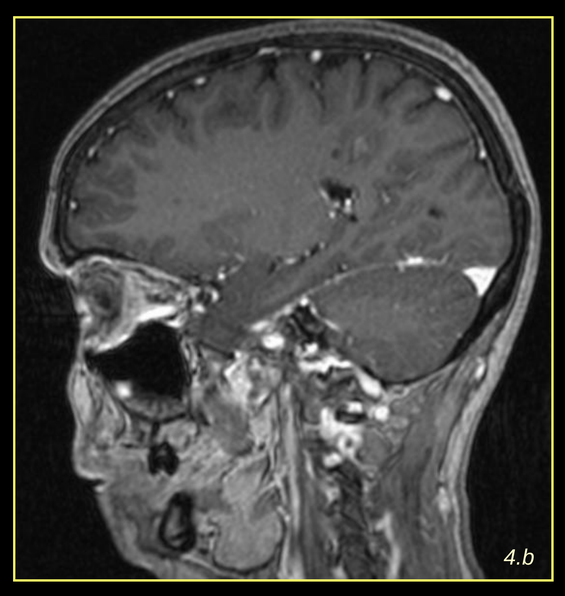

Fig. 4. A 41-year-old woman with MS. a) Sagital FLAIR image. b) Axial post-contrast T1-WI.

Conclusion

A thorough analysis of MRI is a useful diagnostic tool in differentiating TDLs from intracranial neoplasm, which is the most relevant differential diagnosis in these cases, and may therefore reduce the indication for unnecessary surgical biopsy.

References

1. G. Comi. Multiple sclerosis: pseudotumoral forms. Neurol Sci (2004) 25:S374–S379 2. Lucchinetti et al. Clinical and radiographic spectrum of pathologically confirmed tumefactive multiple sclerosis. Brain (2008), 131, 1759-1775. 3. G. Luccicheneti, et al. Atypical multiple sclerosis: MRI findings and differential diagnosis. Neurol Sci (2004) 25:S356–S360. 4. M Fillippi, et al. MRI and the diagnosis of mulltiple sclerosis: expanding the concept of "no better explanation". Lancet Neurol 2006; 5:841-52.